



PRESENTING CLINICAL SIGNS

History: Presented for dental and facial twitches one month earlier. History of managed diabetes. Chronic cough. Radiographs reveal tracheal collapse and concern for a mass. ECG – sinus rhythm.

DATE

2/16/22

ECHOCARDIOGRAPHIC FINDINGS

2D, M-mode, and Doppler study. This exam is compared to the one performed 8/10/21.

PERFORMED BY:

Kim Liedberg

Left atrial size is normal. The mitral valve is normal. Left ventricular dimensions are normal. Left ventricular systolic function is hyperdynamic. The aorta and aortic valve appear normal, though trace aortic insufficiency is present. Right atrial and right ventricular dimensions are normal. The tricuspid valve appears normal, though trace tricuspid regurgitation is present. The pulmonary artery and pulmonic valve are normal. No pericardial effusion or cardiac masses are seen.

INTERPRETED BY

Keith Blass, DVM,
MS, DACVIM
(Cardiology)

LA/Ao – 1.40
LVIDd – 25.2 mm
LVIDs – 13.0 mm
FS – 48%
LVOT – 1.22 m/s
RVOT – 0.92 m/s

PATIENT

Cinnamon Tarczewski

ASSESSMENT/RECOMMENDATIONS

Normal echocardiogram

SPECIES

Canine

This examination demonstrates no evidence of structural heart disease, as trace regurgitation of blood across the tricuspid and aortic valves can be considered normal physiologic variants. As such, there does not appear to be a cardiac contribution to Cinnamon’s cough.

No evidence of a heart base mass is appreciated in the image set.

BREED

Bichon Frise

Cinnamon’s cardiovascular risk for general anesthesia is low based on this exam, and there are no contraindications to the use of any specific anesthetic agents.

No therapy is recommended based on this exam.

SEX

FS

A recheck echocardiogram is recommended if new physical exam and/or clinical abnormalities suggestive of cardiac dysfunction develop.

AGE

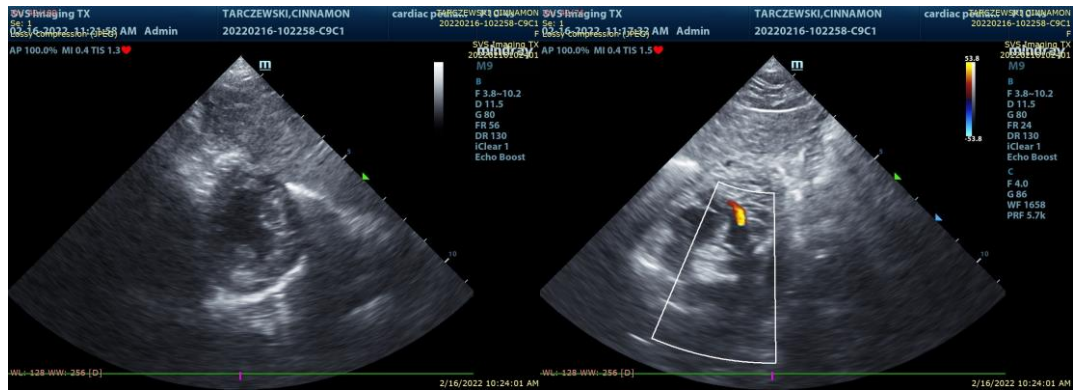
15 y

WEIGHT

21.6 lb

HOSPITAL NAME

SVS Imaging WI



REFERRING VET

Dr. Krisp

The information and recommendations provided are based on the images presented by the



referring veterinarian. No evaluation can be communicated regarding pathology that was not visible in the image/video clips provided.

DATE

2/16/22

Thank you for this referral. If the clinical or image interpretation does not parallel your findings or if I can be of any further assistance please contact me.

PERFORMED BY: Keith Blass, DVM, MS, DACVIM (Cardiology)

KeithBlass@gmail.com
631-804-5754

Kim Liedberg

INTERPRETED BY

Keith Blass, DVM,
MS, DACVIM
(Cardiology)

PATIENT

Cinnamon Tarczewski

SPECIES

Canine

BREED

Bichon Frise

SEX

FS

AGE

15 y

WEIGHT

21.6 lb

HOSPITAL NAME

SVS Imaging WI

REFERRING VET

Dr. Krisp